



ORIGINAL ARTICLE

## Magnetic resonance enterography in pediatric celiac disease<sup>☆</sup>



Gonca Koc<sup>a,\*</sup>, Selim Doganay<sup>a</sup>, Eylem Sevinc<sup>b</sup>, Kemal Deniz<sup>c</sup>, Govind Chavhan<sup>d</sup>, Sureyya B. Gorkem<sup>a</sup>, Neslihan Karacabey<sup>e</sup>, Mehmet S. Dogan<sup>a</sup>, Abdulhakim Coskun<sup>a</sup>, Duran Aslan<sup>e</sup>

<sup>a</sup> Erciyes University Faculty of Medicine, Department of Pediatric Radiology, Kayseri, Turkey

<sup>b</sup> Kayseri Research and Training Hospital, Emel-Mehmet Tarman Children's Hospital, Department of Pediatric Gastroenterology, Kayseri, Turkey

<sup>c</sup> Erciyes University Faculty of Medicine, Department of Pathology, Kayseri, Turkey

<sup>d</sup> University of Toronto, The Hospital for Sick Children and Medical Imaging, Department of Diagnostic Imaging, Toronto, Canada

<sup>e</sup> Erciyes University Faculty of Medicine, Department of Pediatric Gastroenterology, Kayseri, Turkey

Received 15 June 2016; accepted 3 November 2016

Available online 31 January 2017

### KEYWORDS

Celiac disease;  
Magnetic resonance  
enterography;  
Pediatrics

### Abstract

**Objective:** To assess if magnetic resonance enterography is capable of showing evidence/extent of disease in pediatric patients with biopsy-proven celiac disease by comparing with a control group, and to correlate the magnetic resonance enterography findings with anti-endomysial antibody level, which is an indicator of gluten-free dietary compliance.

**Methods:** Thirty-one pediatric patients (mean age  $11.7 \pm 3.1$  years) with biopsy-proven celiac disease and 40 pediatric patients as a control group were recruited in the study. The magnetic resonance enterography images of both patients with celiac disease and those of the control group were evaluated by two pediatric radiologists in a blinded manner for the mucosal pattern, presence of wall thickening, luminal distention of the small bowel, and extra-intestinal findings. Patient charts were reviewed to note clinical features and laboratory findings. The histopathologic review of the duodenal biopsies was re-conducted.

**Results:** The mean duration of the disease was  $5.6 \pm 1.8$  years (range: 3–7.2 years). In 24 (77%) of the patients, anti-endomysial antibody levels were elevated (mean  $119.2 \pm 66.6$  RU/mL). Magnetic resonance enterography revealed normal fold pattern in all the patients. Ten (32%) patients had enlarged mesenteric lymph nodes.

<sup>☆</sup> Please cite this article as: Koc G, Doganay S, Sevinc E, Deniz K, Chavhan G, Gorkem SB, et al. Magnetic resonance enterography in pediatric celiac disease. J Pediatr (Rio J). 2017;93:413–9.

\* Corresponding author.

E-mail: [ggulkoc@gmail.com](mailto:ggulkoc@gmail.com) (G. Koc).

**PALAVRAS-CHAVE**

Doença celíaca;  
Enterografia por  
ressonância  
magnética;  
Pediatria

**Conclusion:** Although a majority of the patients had elevated anti-endomysial antibody levels indicating poor dietary compliance, magnetic resonance enterography did not show any mucosal abnormality associated with the inability of magnetic resonance enterography to detect mild/early changes of celiac disease in children. Therefore, it may not be useful for the follow-up of pediatric celiac disease.

© 2017 Sociedade Brasileira de Pediatria. Published by Elsevier Editora Ltda. This is an open access article under the CC BY-NC-ND license (<http://creativecommons.org/licenses/by-nc-nd/4.0/>).

**A enterografia por ressonância magnética na doença celíaca pediátrica****Resumo**

**Objetivo:** Avaliar se a enterografia por ressonância magnética consegue comprovar/mostrar a extensão da doença em pacientes pediátricos com doença celíaca comprovada por biópsia comparando com um grupo de controle e correlacionar os achados da enterografia por ressonância magnética com o nível de anticorpo antiendomísio indicador de dieta sem glúten.

**Métodos:** 31 pacientes pediátricos (idade média entre  $11,7 \pm 3,1$  anos) com doença celíaca comprovada por biópsia e 40 pacientes pediátricos em um grupo de controle foram recrutados no estudo. As imagens da enterografia por ressonância magnética dos pacientes com doença celíaca e no grupo de controle foram avaliadas por dois radiologistas pediátricos às cegas para o padrão da mucosa, presença de espessamento da parede, dilatação luminal do intestino delgado e achados extraintestinais. Os prontuários dos pacientes foram revisados para anotação de características clínicas e achados laboratoriais. A avaliação histopatológica das biópsias duodenais foi feita novamente.

**Resultados:** A duração média da doença foi  $5,6 \pm 1,8$  anos (faixa de 3-7,2 anos). Em 24 (77%) dos pacientes, os níveis anticorpo antiendomísio estavam elevados (média  $119,2 \pm 66,6$  RU/mL). A enterografia por ressonância magnética revelou um padrão de pregas normal em todos os pacientes. 10 (32%) dos pacientes apresentaram gânglios linfáticos mesentéricos aumentados.

**Conclusão:** Apesar de a maioria dos pacientes possuir níveis elevados de anticorpo antiendomísio, indicando uma dieta pobre, a enterografia por ressonância magnética não mostrou nenhuma anomalia na mucosa associada à incapacidade de a enterografia por ressonância magnética detectar alterações leves/precoces de doença celíaca nas crianças. Portanto, ela pode não ser útil no acompanhamento da doença celíaca pediátrica.

© 2017 Sociedade Brasileira de Pediatria. Publicado por Elsevier Editora Ltda. Este é um artigo Open Access sob uma licença CC BY-NC-ND (<http://creativecommons.org/licenses/by-nc-nd/4.0/>).

**Introduction**

Celiac disease (CD), a malabsorption syndrome with an autoimmune origin, affects approximately 1% of the population.<sup>1,2</sup> The incidence of CD has increased over the decades, presumably due to increased exposure to gluten, awareness of the broad spectrum of clinical presentation, and the availability of sensitive and specific diagnostic tools.<sup>3-6</sup> However, the 'iceberg model' indicates the extent of undiagnosed population with CD.<sup>7</sup> Thus, CD represents a substantial health problem worldwide, affecting both adults and the pediatric population.<sup>8</sup>

In genetically susceptible children, the disease is triggered by exposure to gluten-containing foods. It predominantly affects the duodenum and jejunum; however, the entire small bowel can be involved. The mucosal changes are characterized by villous atrophy, crypt hyperplasia, thickening of the basement membrane under the surface of epithelium, reduced number of goblet cells, and signs of inflammation.<sup>9</sup> The clinical features are broad and nonspecific. The spectrum of clinical presentation in CD may be classified as: (a) classical form, related with intestinal symptoms and predominantly diagnosed in pediatric patients;

(b) atypical form, presentation often with extra-intestinal symptoms such as iron deficiency; (c) silent form; and (d) latent form, patients are asymptomatic and diagnosed during screening due to presence of family history or CD-related conditions, such as type 1 diabetes mellitus, Down syndrome, and juvenile idiopathic arthritis. In latent form, the serologic tests are positive when accompanied with either no histopathologic change in the intestine or only an increase in intraepithelial lymphocytes (Marsh stage 1). The positivity of the serological tests including anti-endomysial (EMA) and anti-tissue transglutaminase (tTG) antibodies in the course of exposure to gluten-containing food and both serological and clinical improvement following gluten-free diet aid in making the diagnosis of CD. The definitive diagnosis is established by endoscopic duodenal or jejunal biopsy.<sup>10</sup>

The characteristic imaging finding of CD is small bowel mucosal fold abnormality, which includes blunting of folds, reduction in the number of jejunal folds, and increase in the number of ileal folds depending on the extent and degree of involvement. These mucosal fold changes have traditionally been evaluated using barium studies. Magnetic resonance enterography (MRE) is a relatively new but well-established radiation-free method for bowel assessment, particularly

**Table 1** Patient groups according to Marsh classification.

Clinical type of CD	Marsh score	Number of patients
Latent	1	2 (100%)
Silent	2	3 (100%)
Atypical	2	2 (40%)
	3	3 (60%)
Classical	2	2 (10%)
	3	19 (90%)

CD, celiac disease.

in inflammatory bowel disease.<sup>11,12</sup> Since MRE enables visualization of the entire small bowel, it has been shown to be beneficial in determining the extent of the disease, CD-related complications including ulcerative jejunoileitis and malignancies, and refractory CD in patients with persisting symptoms despite gluten-free diet.<sup>13–16</sup> However, the studies focused on CD using MRE were conducted particularly in adult study groups and there is scarcity of such studies in the literature evaluating findings of CD by MRE in children.<sup>17</sup>

The histopathologic examination of the patients with CD does not give sufficient information about the extent of the disease, since it is confined to duodenum and proximal jejunum. Thus, the purpose of this prospective, single center study was to determine if MRE is capable of showing extent of the disease in pediatric patients with biopsy proven CD by comparing with a control group and correlating the MRE findings with anti-EMA level, which is an indicator of gluten-free dietary compliance.<sup>18</sup>

## Materials and methods

### Patients

This study was approved by the institutional review board and is compatible with Declaration of Helsinki. Written informed consent was obtained from the parents of all patients. It was conducted between January 2014 and January 2015. The patients who were being followed up with the diagnosis of CD by the pediatric gastroenterology clinics of this institution were recruited in the study. The inclusion criteria included children above 5 years of age with the ability to comply with breath-holding instructions and stay still throughout the procedure without need for sedation. The diagnosis of CD was based on the criteria outlined by the European Society for Paediatric Gastroenterology, Hepatology, and Nutrition.<sup>8</sup>

### Patient chart review

Patient charts were reviewed prior to MRE examinations for clinical features and laboratory findings, and subsequently recorded by a pediatric gastroenterologist (E.S.). The histopathologic examinations of the previously obtained (at the time of diagnosis) duodenal biopsies of the patients were re-analyzed by a pathologist (K.D.) who was blinded to clinical features. The patients were scored and grouped according to the Marsh classification, which is obtained from the histopathologic examination and reflects the severity

of the disease (Table 1). Marsh classification consists of four stages (0–3) constructed based on several features of biopsy specimen: Stage 0 reflects normal biopsy, while stage 1, stage 2, and stage 3 are predominantly associated with increased intraepithelial lymphocytes, crypt hyperplasia, and villous atrophy, respectively.<sup>19,9</sup>

### MR enterography technique

Patients were scanned by a 1.5T clinical scanner (Magnetom, Aera – Siemens Healthcare; Erlangen, Germany) with an 18-channel body coil. Prior to MRE examination, 24 patients with CD were non-compliant, while eight were compliant with gluten-free diet. The preparation for MRE consisted of fasting for 4–6 h and administration of mannitol solution (3%) as an oral contrast medium. MRE performed in supine position with the following sequences: Coronal T2-weighted half-Fourier acquisition single-shot turbo spin-echo (HASTE) in order to evaluate the distension of the small intestine, CINE imaging with coronal fast imaging with steady-state free precession (True-FISP), axial (with fat saturation) and coronal True-FISP, coronal T2-weighted HASTE with fat saturation, axial single-shot fast spin-echo echo planar diffusion weighted imaging ( $b = 50, 400, 800 \text{ s/mm}^2$ ), and prior to and following, intravenous gadolinium-based contrast medium injection (0.1 mmol/kg) axial and coronal 3D T1-weighted volumetric interpolated breath-hold examination with fat saturation (VIBE). Hyoscine butylbromide (Buscopan; Boehringer – Ingelheim, Germany) was administered intravenously twice slowly over 2 min at a dose of 0.3 mg/kg, with a maximum dose of 20 mg to eliminate bowel movement and contraction; following the CINE imaging and prior to contrast agent administration. The sequence parameters are presented in Table 2.

### Image analysis

The MRE examinations of 40 pediatric patients (mean age:  $8.0 \pm 1.2$  years; age range: 5–8.4 years), as a control group, who were scanned with the suspicion of inflammatory bowel disease but had normal imaging findings, and the patient group with the diagnosis of CD were anonymized and sent back to a clinical picture-archiving and communication system by a pediatric radiologist (M.S.D.) who did not take part in the image evaluation.

The images were independently assessed by two pediatric radiologists (S.D., G.K., four and five years of experience in reading MREs, respectively) in a manner blinded to the patients' clinical information. Each MRE was scored for the absence (0) or presence (1) of one-fold pattern abnormalities of the duodenal, jejunal, and ileal loops; (2) enhancement, diffusion restriction, and increased thickness of the small bowel wall; (3) increased diameter of the bowel loops, (4) intussusception, and (5) mesenteric lymph nodes, fatty infiltration, and vascular engorgement. They specifically looked for duodenal fold loss, ilealization of the jejunum (<three folds per inch), jejunization of the ileum (>five folds per inch), and global loss of valvulae. The wall thickness of the jejunum and ileum was measured in mm using the T2-weighted HASTE sequence by avoiding the interfaces of intestinal folds and mucosal folds in order to

**Table 2** Sequence parameters of MRI acquisition.

Sequences	Parameters					
	TR (ms)	TE (ms)	Slice thickness (mm)	Gap (mm)	FA	Matrix
T2 HASTE	2000	91	5	1	–	320 × 320
True-FISP	3.21	1.04	4	1	50	256 × 256
T1 VIBE	4.36	1.91	3	0	10	256 × 180
Cine true-FISP	3.21	1.04	4	1	50	256 × 180
Diffusion	6810	62	5	5	–	256 × 256

MRI, magnetic resonance imaging; HASTE, half-Fourier acquisition single-shot turbo spin-echo; True-FISP, fast imaging with steady-state free precession; VIBE, volumetric interpolated breath-hold examination; TR, time of repetition; TE, time of echo; FA, flip angle.

prevent overestimation of the thickness. True-FISP and VIBE sequences were not preferred due to vulnerability to the black boundary artifact that would result in incorrect measurements. The mesenteric lymph nodes with a short-axis diameter measuring greater than 1 cm were considered as pathologic.

Additionally, the radiologists were asked to rate the images of each patient with an incremental three-point scale (0 = inadequate, 1 = moderate, 2 = adequate) for small bowel distention.

## Results

A total of 45 pediatric patients with the diagnosis of CD were recruited in the study initially. Nine of the patients whose duodenal biopsy and histopathologic examination were carried out in another center and five patients who could not tolerate the MRE acquisition (due to associated chronic diseases such as IgA deficiency, Turner syndrome, type 1 diabetes mellitus, and Down syndrome that might have caused the patients to be incompatible) were excluded.

Finally, 31 children with CD (ten boys and 21 girls; mean age  $11.7 \pm 3.1$  years and age range 6–16 years) were included. Twenty-one (68%) patients out of 31 were categorized as classical, five (16%) as atypical, two (6%) as latent, and three (10%) as silent CD. The presenting symptom for all the patients with classical CD was chronic diarrhea, abdominal distension, and pain. Patients with atypical CD presented with constipation and accompanying iron deficiency anemia resistant to oral Fe. There were no signs/symptoms of the patients with latent and silent CD. They were diagnosed by screening conducted due to increased risk for CD because of family history.

The mean duration of the disease was  $5.6 \pm 1.8$  years (range 3–7.2 years). In 24 patients who were non-compliant with the gluten-free diet, EMA levels were elevated (mean  $119.2 \pm 66.6$  RU/mL and range 0–200 RU/mL). In this institution, anti-EMA levels of 0–20 RU/mL are considered to be within normal limits while levels of 21–200 RU/mL are considered elevated. The average time between measurement of the serum EMA level and MRE examination was  $12 \pm 3.0$  days (range 8–16 days). Prior to MRE examination, patients with non-elevated EMA and ten out of 24 patients with elevated EMA were all free of symptoms. Fourteen patients with elevated EMA presented with either abdominal pain or diarrhea. Patient demographics and laboratory findings are listed in Table 3.

The two radiologists rated all the examinations of the patients with CD and the control group as '0': fold pattern was interpreted as normal in all the patients. There was no duodenal fold loss, ilealization of the jejunum, jejunalization of the ileum, or global loss of valvulae. The wall thickness was within normal limits (mean:  $1.5 \pm 0.26$  and  $1.58 \pm 0.28$  mm for jejunum and ileum, respectively). Abnormal enhancement or diffusion restriction of the bowel wall was not encountered (Fig. 1).

Ten patients out of 31 (32%) were detected to have mesenteric lymph nodes with >1 cm short-axis diameter. No other extra-intestinal abnormalities were detected.

The radiologists rated the images of patients with CD as 'adequate' in 25 (81%) and 27 (87%) out of the 31 examinations (substantial inter reader agreement,  $\kappa = 0.73$ ), and the images of control group patients as 'adequate' in 34 (85%) and 32 (80%) out of 40, respectively (almost perfect inter-reader agreement,  $\kappa = 0.82$ ), while the rest were scored as 'moderate' for small bowel distention.

Examinations were well tolerated and no significant adverse effects occurred.

## Discussion

This study performed to assess MRE findings of CD in children did not reveal any imaging abnormalities. Several studies have shown fold pattern abnormalities on imaging in patients with uncomplicated CD.<sup>20,21</sup> The findings include decreased number of jejunal folds (<three per inch) and increased number of ileal folds (>five folds per inch); the combination of these two findings is known as 'reversed jejunoileal fold pattern.' The other intestinal findings included distention and increased wall thickness of small intestine, especially affecting the jejunum. However, Laghi et al.<sup>17</sup> and Tomei et al.<sup>13</sup> have reported absence of MRE findings in 29% and 42% of their patients, respectively, including adults and children with biopsy-proven CD. The current study group, being exclusively pediatric patients, may not have developed the intestinal mucosal damage observed in adult patients. This is supported by the fact that 29% (9/31) of the children had mild mucosal changes reflected by Marsh stage 1 and 2, which may not be shown by MRE.

Five out of 31 (16%) patients in the study group were diagnosed with either latent or silent CD. The histopathologic examination of the duodenal biopsies of these patients revealed either Marsh stage 1 or 2. Tomei et al.<sup>13</sup> reported

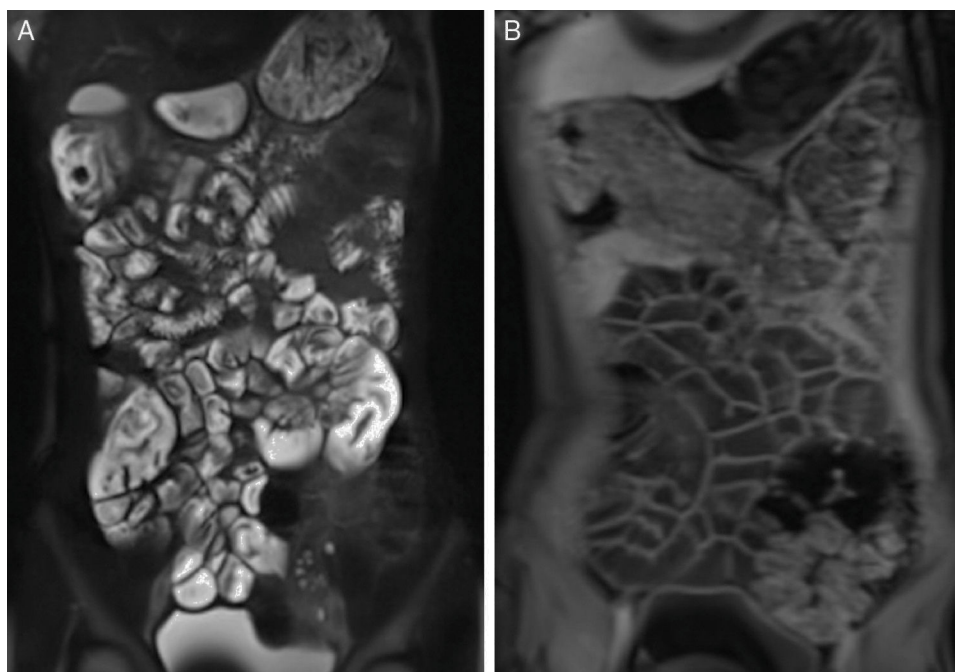
**Table 3** Clinical and laboratory features of the study group.

Patients	Gender	Age (years)	Height (cm)	Weight (kg)	BMI	EMA (RU/mL)	Marsh score <sup>a</sup>	Clinical type	Duration of follow-up (years)
1	F	16	170 (25 p)	43 (25 p)	14.9	0	1	Latent	7
2	M	7	105 (<3 p)	15 (<3 p)	13.6	100	3	Classical	3
3	F	13	160 (50–75 p)	43 (10–25 p)	16.2	10	2	Atypical	5
4	F	9	128 (25 p)	25 (25 p)	15.3	120	2	Silent	3
5	F	9	131 (50 p)	27 (10–25 p)	15.7	140	2	Atypical	6
6	F	16	163 (3–10 p)	70 (50 p)	26.3	0	3	Classical	7
7	M	9	156 (90 p)	32 (75 p)	13.1	150	1	Latent	5
8	F	14	134 (<3 p)	37 (3–10 p)	20.6	10	3	Classical	7
9	F	11	129 (3–10 p)	26 (<3 p)	15.6	200	2	Classical	5
10	F	13	160 (75 p)	46 (75 p)	18	200	3	Classical	7
11	F	13	150 (10–25 p)	38 (3–10 p)	17	200	3	Classical	7
12	M	13	178 (90 p)	45 (50 p)	14.2	150	3	Atypical	7
13	F	16	168 (25–50 p)	46 (10–25 p)	16.3	10	2	Silent	7
14	M	14	168 (50 p)	27 (3 p)	9.6	130	3	Classical	7
15	M	6	105 (<3 p)	18 (10–25 p)	16.3	120	3	Classical	3
16	F	9	130 (75 p)	43 (90–97 p)	25.4	10	2	Silent	4
17	F	15	169 (25–50 p)	44 (<3 p)	15.4	150	3	Classical	7
18	F	10	155 (97 p)	33 (50–75 p)	14	160	3	Classical	3
19	M	16	169 (25–50 p)	54 (3–10 p)	18.9	170	3	Classical	7
20	M	11	136 (10–25 p)	43 (10–25 p)	23.2	10	3	Atypical	7
21	F	12	168 (97 p)	33 (10–25 p)	11.7	167	3	Classical	5
22	M	17	176 (50–75 p)	54 (10 p)	17.4	145	3	Classical	7
23	F	8	118 (3–10 p)	29 (50–75 p)	20.8	140	3	Classical	3
24	F	7	97.5 (<3 p)	17 (<3 p)	18.7	200	3	Atypical	3
25	M	11	170 (>97 p)	35 (25–50 p)	12.1	133	3	Classical	3
26	M	12	157 (50 p)	23.8 (<3 p)	9.7	122	3	Classical	7
27	F	16	170 (25–50 p)	50 (<3 p)	17.3	166	3	Classical	3
28	F	9	156 (>97 p)	45 (>97 p)	18.5	150	3	Classical	7.2
29	F	12	158 (50–75 p)	40 (25–50 p)	16	110	3	Classical	7
30	F	11	165 (>97 p)	33 (25–50 p)	12.1	145	3	Classical	7
31	F	9	135 (50–75 p)	23 (3–10 p)	12.6	177	2	Classical	4

BMI, body mass index; <15, underweight; 15–24, normal; >24, overweight; EMA, anti-endomysial antibody; 0–20 RU/mL, normal; 20–200 RU/mL, elevated; p, percentile.

<sup>a</sup> The duodenal biopsies were performed at the time of diagnosis.





**Figure 1** 16-Year-old female patient with diagnosis of celiac disease; T2-weighted HASTE (A) and T1-weighted fat-saturated VIBE (B) images acquired following intravenous contrast administration reveal no fold pattern abnormalities of the intestines. HASTE, half-Fourier acquisition single-shot turbo spin-echo; VIBE, volumetric interpolated breath-hold examination.

that 90% of their patients diagnosed with silent CD had normal fold pattern. Although there is a limited number of studies focusing on MRE findings of CD, the large experience in Crohn's disease has revealed the inability of MRE to exhibit mucosal changes, but for inflammatory wall involvement.<sup>22</sup> In accordance with this fact, in the current study all the patients diagnosed with either silent or latent CD had no fold pattern abnormalities on MRE. In fact, in this study that consisted of a majority (68%) of children with the classical form, no fold abnormalities were seen in any patients.

Increased levels of EMA were detected in 77% of the patients prior to MRE acquisition. The antibodies including EMA and tTG are essential for the follow-up of patients with CD and have been reported to have a good correlation with gluten-free dietary compliance in both adult and pediatric patients.<sup>23</sup> Increased levels of EMA indicate non-compliance of the patient, *i.e.*, not strictly adhering to gluten-free diet.<sup>24</sup> van den Bosch et al. reported a good correlation between response to gluten-free diet and enteroclysis findings as compared to biopsy in adults with CD.<sup>23</sup> However, there are no such studies related to MRE. An alternative explanation, at least in part, for absence of imaging finding in patients with normal anti-EMA levels could be prevention of mucosal damage with gluten-free diet.

The extraluminal radiologic manifestations of CD include enlarged mesenteric lymph nodes, mesenteric vascular engorgement, and transient intussusceptions. Enlarged (>1 cm short-axis diameter) mesenteric lymph nodes are the most common extraluminal finding associated with CD, seen in up to 42% cases.<sup>25</sup> The size of lymph nodes decreases with treatment with gluten-free diet and their persistence should raise the suspicion of lymphoma.<sup>25,26</sup> These

hypertrophic lymph nodes may act as an inception point for intussusception, which can be the initial presentation in 57% of the patients with CD.<sup>27</sup> Mesenteric vascular engorgement is a nonspecific sign of the disease. While enlarged mesenteric lymph nodes were the only and the most common extraluminal finding in the current patients, intussusception and vascular engorgement were not detected.

This study has a few limitations. Although the total number of study patients was relatively acceptable, the patient group was diverse, including patients with classical, atypical, silent, and latent CD. Since the both patients with silent and latent CD had lower Marsh scores associated with mild mucosal changes that might have resulted in lack of MRE findings, a study conducted with a larger, homogenized patient group may be worth further investigation. Since radiological follow-up was not performed, serial MRE images acquired at the time of diagnosis and following initiation of gluten-free diet would help assess radiological changes in the course of disease. Lastly, the histopathologic examination of the duodenal biopsy was performed at the time of diagnosis. The comparison of recently obtained biopsy results with imaging findings would enable making a more plausible hypothesis on the relation of imaging findings and histopathologic changes.

In conclusion, despite elevated EMA levels in the majority of children, indicating poor dietary compliance, this study did not show any significant MRE findings in biopsy-proven CD, indicating inability of MRE to detect mild and/or early mucosal damage (suggested by lower Marsh score) seen in children with CD. Therefore, it may not be useful as a diagnostic test for CD or for follow-up. However, as indicated by some authors previously,<sup>17</sup> MRE may be useful for detection of suspected complications of CD, such

as stricture and lymphoma, evaluation of CD non-responsive to gluten-free diet, and to exclude alternative diagnoses.

## Conflicts of interest

The authors declare no conflicts of interest.

## References

- Gujral N, Freeman HJ, Thomson AB. Celiac disease: prevalence, diagnosis, pathogenesis and treatment. *World J Gastroenterol*. 2012;18:6036–59.
- Dalgic B, Sari S, Basturk B, Ensari A, Egritas O, Bukulmez A, et al. Prevalence of celiac disease in healthy Turkish school children. *Am J Gastroenterol*. 2011;106:1512–7.
- Kelly CP, Bai JC, Liu E, Leffler DA. Advances in diagnosis and management of celiac disease. *Gastroenterology*. 2015;148:1175–86.
- Riddle MS, Murray JA, Porter CK. The incidence and risk of celiac disease in a healthy US adult population. *Am J Gastroenterol*. 2012;107:1248–55.
- Vilppula A, Kaukinen K, Luostarinen L, Krekelä I, Patrikainen H, Valve R, et al. Increasing prevalence and high incidence of celiac disease in elderly people: a population-based study. *BMC Gastroenterol*. 2009;9:49.
- Lohi S, Mustalahti K, Kaukinen K, Laurila K, Collin P, Rissanen H, et al. Increasing prevalence of coeliac disease over time. *Aliment Pharmacol Ther*. 2007;26:1217–25.
- Fasano A, Catassi C. Current approaches to diagnosis and treatment of celiac disease: an evolving spectrum. *Gastroenterology*. 2001;120:636–51.
- Husby S, Koletzko S, Korponay-Szabó IR, Mearin ML, Phillips A, Shamir R, et al. European Society for Pediatric Gastroenterology, Hepatology, and Nutrition guidelines for the diagnosis of coeliac disease. *J Pediatr Gastroenterol Nutr*. 2012;54:136–60.
- Dickson BC, Streutker CJ, Chetty R. Coeliac disease: an update for pathologists. *J Clin Pathol*. 2006;59:1008–16.
- Ciclitira PJ, King AL, Fraser JS. AGA technical review on Celiac Sprue. *American Gastroenterological Association. Gastroenterology*. 2001;120:1526–40.
- Grand DJ, Guglielmo FF, Al-Hawary MM. MR enterography in Crohn's disease: current consensus on optimal imaging technique and future advances from the SAR Crohn's disease-focused panel. *Abdom Imaging*. 2015;40:953–64.
- Gücer FI, Senturk S, Özkanlı S, Yilmabasar MG, Köroglu GA, Acar M. Evaluation of Crohn's disease activity by MR enterography: derivation and histopathological comparison of an MR-based activity index. *Eur J Radiol*. 2015;84:1829–34.
- Tomei E, Diacinti D, Stagnitti A, Marini M, Laghi A, Passariello R, et al. MR enterography: relationship between intestinal fold pattern and the clinical presentation of adult celiac disease. *J Magn Reson Imaging*. 2012;36:183–7.
- Van Weyenberg SJ, Meijerink MR, Jacobs MA, van Kuijk C, Mulder CJ, van Waesberghe JH. MR enteroclysis in refractory celiac disease: proposal and validation of a severity scoring system. *Radiology*. 2011;259:151–61.
- Masselli G, Picarelli A, Gualdi G. Celiac disease: MR enterography and contrast enhanced MRI. *Abdom Imaging*. 2010;35:399–406.
- Tomei E, Semelka RC, Braga L, Laghi A, Paolantonio P, Marini M, et al. Adult celiac disease: what is the role of MRI? *J Magn Reson Imaging*. 2006;24:625–9.
- Laghi A, Paolantonio P, Catalano C, Dito L, Carbone I, Barbato M, et al. MR imaging of the small bowel using polyethylene glycol solution as an oral contrast agent in adults and children with celiac disease: preliminary observations. *AJR Am J Roentgenol*. 2003;180:191–4.
- Rubio-Tapia A, Murray JA. Classification and management of refractory coeliac disease. *Gut*. 2010;59:547–57.
- Marsh MN. Gluten, major histocompatibility complex, and the small intestine. A molecular and immunobiologic approach to the spectrum of gluten sensitivity ('celiac sprue'). *Gastroenterology*. 1992;102:330–54.
- Soyer P, Boudiaf M, Dray X, Fargeaudou Y, Vahedi K, Aout M, et al. CT enteroclysis features of uncomplicated celiac disease: retrospective analysis of 44 patients. *Radiology*. 2009;253:416–24.
- Muller WF. Adult celiac disease. In: Sellink JL, Miller RE, editors. *Radiology of the small bowel: modern enteroclysis technique and atlas*. The Hague, The Netherlands: Nijhoff; 1982.
- Tillack C, Seiderer J, Brand S, Göke B, Reiser MF, Schaefer C, et al. Correlation of magnetic resonance enteroclysis (MRE) and wireless capsule endoscopy (CE) in the diagnosis of small bowel lesions in Crohn's disease. *Inflamm Bowel Dis*. 2008;14:1219–28.
- Sugai E, Nachman F, Vázquez H, González A, Andrenacci P, Czech A, et al. Dynamics of celiac disease-specific serology after initiation of a gluten-free diet and use in the assessment of compliance with treatment. *Dig Liver Dis*. 2010;42:352–8.
- van den Bosch HC, Tjon a Tham RT, Gooszen AW, Fauquenot-Nollen JM, Lamers CB. Celiac disease: small-bowel enteroclysis findings in adult patients treated with a gluten-free diet. *Radiology*. 1996;201:803–8.
- Lohan DG, Alhajeri AN, Cronin CG, Roche CJ, Murphy JM. MR enterography of small-bowel lymphoma: potential for suggestion of histologic subtype and the presence of underlying celiac disease. *AJR Am J Roentgenol*. 2008;190:287–93.
- Lucey BC, Stuhlfaut JW, Soto JA. Mesenteric lymph nodes seen at imaging: causes and significance. *Radiographics*. 2005;25:351–65.
- Gonda TA, Khan SU, Cheng J, Lewis SK, Rubin M, Green PH. Association of intussusception and celiac disease in adults. *Dig Dis Sci*. 2010;55:2899–903.